

Neuropathic pain in vulvar vestibulitis: Diagnosis and treatment

E. Vincenti*
and A. Graziottin**

**Anaesthesia and Intensive Care Department, USSL13 del Veneto, Dolo, Venezia,*
 ***Center of Gynecology and Medical Sexology, H. San Raffaele Resnati, Milano, Italy*

ABSTRACT. *Patients affected by vulvar vestibulitis syndrome (VVS) suffer from symptoms typical of neuropathic pain such as allodynia and hyperalgesia. Because of the severe pain on vestibular touch or attempted vaginal entry, intercourse is increasingly avoided. Pathophysiology of physical symptoms is related to the microscopic findings of proliferation of pain fibers which are also superficialized within the vestibular tissue. Current non-invasive treatment may be useful in a number of patients, but the most severe cases need a stronger approach, such as anaesthetic nervous blocks. Monthly repeated nervous anaesthetic blocks with bupivacaine of the impar ganglion, sacral roots and pudendal nerves, completed by ancillary therapy including antidepressant and anticonvulsant (as gabapentin) drugs, may progressively reduce intensity of pain and its extension. Both decreased ending fibers sprouting induced by periodic anaesthetic blocks sessions and secondary changes of forebrain activity seem to be a rational pathophysiologic explanation of the efficacy of this new and original therapy for VVS' pain.*
 Urodinamica 14: 112-116, 2004

©2004, Editrice Kurtis

INTRODUCTION

Recent findings of histologic and biochemical features of vestibular tissues of patients affected by vulvar vestibulitis syndrome (VVS) (1-3) have stimulated a new and more effective therapy of the cases defined as intractable.

Anaesthetic nervous blocks mainly of the impar ganglion and ancillary therapy with gabapentin have modified the general approach to the treatment of these patients, who were before scheduled for an ablative surgery of the vestibulus, i.e. vestibulectomy. Pathophysiologic considerations are necessary to elucidate the rational basis of our therapeutic approach.

Correspondence

Ezio Vincenti, MD,
 Dipartimento di
 Anestesiologia,
 Ospedale di Dolo,
 Via 29 Aprile, 2,
 30031 Dolo (Venezia), Italy.

E-mail

evincenti@libero.it
 ezio.vincenti@ulss13mirano.ven.it

PATHOPHYSIOLOGIC SCENARIO

An acute aggression to the vulvar vestibulus due to bacterial, fungal or viral infection, to chemical irritants, to coital rubbing when lubrication is lacking, as well as iatrogenic procedures may cause an acute pain, lasting from some days to a few months. This cause an inflammatory response with a typical nociceptive pain, which a correct symptomatic and etiologic approach may resolve (4). When such an irritation becomes chronic, the mast cells become up-regulated. Their production of Nerve Growth Factors (NGF) promotes nerve pain fibers proliferation, which correlates with hyperalgesia, and superficialization of them which causes "allodynia", the perceptive shift from tactile to burning pain (1-4). This explains why pain becomes persistent in spite of every current non-invasive treatment. When nerves work in an abnormal fashion, as they signal pain without an apparent peripheral damage, the term "neuropathic pain" may be used. This pain also describes the process by which the neurons involved in pain transmission are converted from a state of normosensitivity to one in which they are hypersensitive.

Initially, pain is only due to peripheral mechanisms, but later central mechanisms are progressively recruited. The pathophysiology of peripheral neuropathic pain is therefore based both on abnormal peripheral inputs and an abnormal central processing (1-5). Peripheral mechanisms include (a) nociceptors sensibilization, (b) spontaneous activation of primary afferent fibres ectopically firing from the site of lesion and, in addition, (c) the so called "neurogenic inflammation". The latter is characterized by algogenic substances release which may move backwards along the sensory nerves and/or be released by the up-regulated mast cells through a neurogenic activation of their de-granulation. A close interaction between mast cells and pain nerve fibers, with reciprocal potentiation, seems to be a key feature of peripheral neuro-

pathic pain. As far as the central mechanisms are concerned, wind up phenomenon occurs due to the progressive increase of cellular firing following repeated identical electrical stimuli (6). Also, spinal and supraspinal propagation of abnormal local changes caused by peripheral nervous lesion is responsible for an aberrant central elaboration. In the biochemical field, excitatory amino acids and NMDA (n-methyl-d-aspartate) receptors play a crucial role in the genesis of chronic neuropathic pain (6).

The dorsal horn of the spinal cord seems to be extremely important in the beginning and maintenance of neuropathic pain. Very recently, Tsuda et al. (7) have demonstrated that activation of p38 mitogen-activated protein kinase (p38MAPK), in spinal hyperactive microglia of the dorsal horn contributes to pain hypersensitivity to innocuous stimuli (tactile allodynia) following peripheral nerve injury. In fact, intrathecal administration of a specific p38MAPK inhibitor (SB203580) suppresses the development of the nerve injury-induced tactile allodynia. Other investigations (8) show that galectin-1 (one of the endogenous galactoside-binding lectins, involved in a variety of functions, such as neurite outgrowth, synaptic connectivity, cell proliferation and apoptosis) increases in the dorsal horn at 1 to 2 weeks after axotomy and that intrathecal administration of anti-recombinant human galectin-1 antibody partially but significantly attenuates the upregulation of substance P receptor (SPR) in the spinal dorsal horn and the mechanical hypersensitivity induced by the peripheral nerve injury. These data suggest that endogenous galectin-1 may support neuropathic pain after the peripheral nerve injury at least partly by increasing SPR in the dorsal horn.

Tissue injury of almost any kind, but especially peripheral or central neural tissue injury, can lead to long-lasting spinal and supraspinal re-organization that includes the forebrain (9). These forebrain changes may

be adaptive and facilitate functional recovery, or they may be maladaptive, preventing or prolonging the painful condition (9, 10). In an experimental model of heat allodynia, functional brain imaging showed that: (a) the forebrain activity during heat allodynia is different from that during normal heat pain, and (b) during heat allodynia, specific cortical areas, specifically the dorsolateral prefrontal cortex, can attenuate specific components of the pain experience, such as affect, by reducing the functional connectivity of subcortical pathways. The forebrain of patients with chronic neuropathic pain may undergo pathologically induced changes that can impair the clinical response to all forms of treatment.

CLINICAL DIAGNOSIS

Neuropathic pain arising from VVS may clinically be associated with a complex regional pain syndrome (CRPS) (6), early recognized as reflex sympathetic dystrophy. Burning pain, tenderness, sometimes itching, psychological involvement are the main complaints of patients suffering from VVS. Persistent vulvar allodynia and hyperalgesia lead to the avoidance of intercourse, which causes dyspareunia (4). In the absence of appropriate treatment pain tends to worsen and widen in the perineal and bladder area.

Patients with VVS have an increased innervation and/or sensitization of thermoreceptors and nociceptors in their vestibular mucosa. In patients with VVS Bohm-Starke et al. (2) found presence of allodynia to mechanical testing with von Frey filaments (14.3 ± 3.1 mN in the symptomatic posterior area as compared with 158 ± 33.5 mN in healthy subjects), as well as to the pain threshold to heat ($38.6 \pm 0.6^\circ\text{C}$ in patients and 43.8 ± 0.8 in controls); in addition, pain threshold to cold was $21.6 \pm 1.2^\circ\text{C}$ in patients whereas cooling down to 6°C was usually not painful in controls.

The VVS classical definition of Friedrich (11)

about the constellation of symptoms and findings involving, and limited to, the vulvar vestibule that consists of (a) severe pain on vestibular touch or attempted vaginal entry, (b) tenderness to pressure localized within the vulvar vestibule, and (c) physical findings confined to vulvar erythema of various degrees, seems to be always valid only for (a) and (b), since many patients suffering from neuropathic pain may present an apparently normal mucosa without signs of erythema. In fact, according to Bergeron et al. (12) erythema does not appear to be a useful diagnostic criterion; in addition, no active inflammation was seen by biopsies obtained from the vestibular mucosa by analysing cyclooxygenase 2 and inducible nitric oxide synthase (indirect immunohistochemistry method).

THERAPY FOR SEVERE NEUROPATHIC PAIN

A basic therapeutic approach to the VVS is always mandatory (4). Hygienic and behavioural recommendations should be given in order to avoid chronic irritation and maceration of the fragile tissues and improve perineal care. Prevention of yeast's infection recurrences should be maintained with antimycotic oral treatment (4). Food intake should be qualitatively controlled as well, to reduce vestibular irritation during micturition, and to reduce candida's recurrences. Relaxation of the pelvic floor should be obtained through self massage, physiotherapy and/or electromyographic feed-back (13). In fact, treatment of underlying causes but especially of etiologic specific factors (organic and psychologic) must be done before performing an effective analgesic therapy. The Authors have suggested specific guidelines for management of neuropathic pain due to VVS (Table 1) (14).

As a rule, patients with intractable (to conventional therapy) neuropathic pain from VVS need the 2a (invasive, non-surgical) stage of

Table 1 - Guidelines for management of neuropathic pain due to vulvar vestibulitis syndrome.

Stages of treatment (a multimodal interdisciplinary treatment approach)

1. CONVENTIONAL, NON-INVASIVE

- a. Pharmacological
- b. Electromyographic biofeedback of pelvic floor musculature (13)
- c. TNS (transcutaneous nerve stimulation)

2. INVASIVE, NON-SURGICAL

- a. Peripheral anaesthetic blocks (impar ganglion, sacral nerves, pudendal nerves) (14)
- b. Sacral nerves stimulation by implantable catheters (15)

3. SURGICAL (vestibulectomy)

treatment. The pathophysiologic basis of this approach should be looked for in the histologic alterations of vestibular innervation which appears intraepithelially increased in the mucosa of VVS patients. If chronic aggressive factors can transform a normal mucosa into an altered histologic picture (Figure 1), a correct and ad hoc pathophysiologic treatment with periodic anaesthetic blocks can restore the normal innervation.

The persistent efficacy of nervous block therapy may be explained as follows. The anaesthetic block of specific afferent fibres, especially neurovegetative, from an area involved in neuropathic transmission might induce a progressive self-reduction (neuroplasticity) of the hyperplastic peripheral nervous arborization in the intraepithelial field, with a parallel reduction of the neurogenically induced degranulation of the up-regulated mast-cell. In fact, even a transient but repeated anaesthetic deafferentation should be sufficient to modify an altered (excessive) supply of nervous endings, functionally producing allodynia and hyperalgesia as a result of reduced pain threshold. Therefore, we have employed repeated anaesthetic nervous blocks of the impar ganglion (4, 14) which is the last ganglion of the sympathetic chain, with the task of transmitting sympathetic information to and from the perineal area.

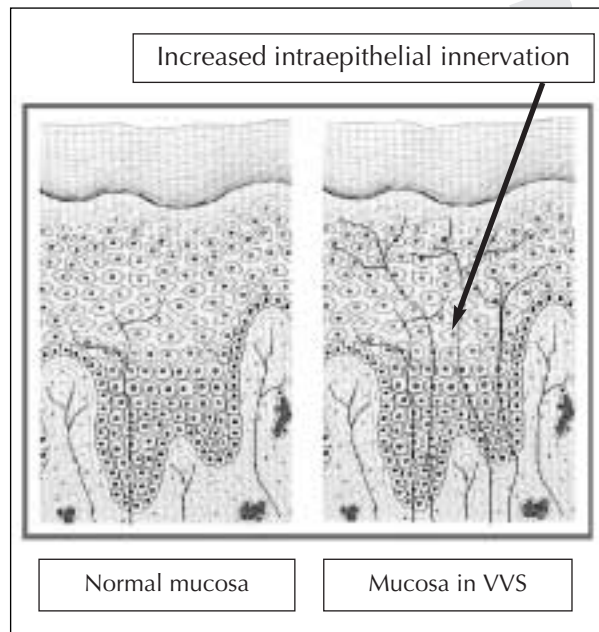


Figure 1 - Schematic pictures of healthy mucosa and mucosa of VVS patients.

RESULTS

As far as materials and methods are concerned, every session of blocks is currently composed of anaesthetic blocks of sacral nerves, pudendal nerves (through perineal way) and finally the impar ganglion (under the guidance of a finger rectally introduced), which is the main target. Plain 0.25% bupivacaine is used in a total volume of no more

than 30 ml per session. 23G needles from 30 to 90 mm are employed.

The correct use of these anaesthetic blocks has offered a dramatic improvement of the clinical conditions by controlling burning pain immediately (onset time less than 2 min). Following the first sessions of anaesthetic blocks, the duration of pain relief is limited to a few hours or some days. After some months, pain-free time becomes longer and longer up to a duration of some weeks. Within 6 months about 80% of patients affected by intractable pain from VVS obtain persistent pain relief rating more than 90% in comparison with the pre-block period.

In order to offer additional comfort when pain relief by block therapy is still not complete, gabapentin and tricyclic antidepressant (amitriptyline) drugs are utilized. Dosage is adjusted to the principle of minimum effective dose or of the dose allowing acceptable minor side effects.

CONCLUSIONS

The anaesthetic nervous blocks monthly performed in the perineal region, including the impar ganglion, seem to be the most effective answer to women affected by severe neuropathic pain due to VVS and resistant to current non-invasive therapy.

REFERENCES

1. Bohm-Starke N., Hilliges M., Falconer C., et al.: Neurochemical characterization of the vestibular nerves in women with vulvar vestibulitis syndrome. *Gynecol. Obstet. Invest.* 48: 270-275, 1999.
2. Bohm-Starke N., Hilliges M., Blomgren B., et al.: Increased blood flow and erythema in posterior vestibular mucosa in vulvar vestibulitis. *Am. J. Obstet. Gynecol.* 98: 1067-1074, 2001.
3. Bohm-Starke N., Hilliges M., Brodda-Jansen G., et al.: Psychophysical evidence of nociceptor sensitization in vulvar vestibulitis Syndrome. *Pain* 94: 177-183, 2001.
4. Graziottin A., Brotto L., Vulvare Vestibulitis Syndrome: clinical approach. *J. Sex. Marital Ther.* 2004 (in press).
5. Woolf C.J.: The pathophysiology of peripheral neuropathic pain: abnormal peripheral input and abnormal central processing. *Acta Neurochir. Suppl.* 58: 125-130, 1993.
6. Dickenson A.H.: A cute for wind up: NMDA receptors antagonists as potential analgesics. *Trends Pharmacol. Sci.* 11: 307-309, 1990.
7. Tsuda M., Mizokoshi A., Shigemoto-Mogami Y., et al.: Activation of p38 mitogen-activated protein kinase in spinal hyperactive microglia contributes to pain hypersensitivity following peripheral nerve injury. *Glia* 45: 89-95, 2004.
8. Imbe H., Okamoto K., Kadoya T., et al.: Galectin-1 is involved in the potentiation of neuropathic pain in the dorsal horn. *Brain Res.* 993: 72-83, 2003.
9. Casey K.L., Lorenz J., Minoshima S.: Insights into the pathophysiology of neuropathic pain through functional brain imaging. *Exp. Neurol.* 184 (Suppl. 1): 80-8, 2003.
10. Merskey H., Bogduk N.: Classification of chronic pain. Seattle, IASP Press, 1994.
11. Friedrich E.G.: Vulvar Vestibulitis Syndrome. *J. Reprod. Med.* 32: 110-114, 1987.
12. Bergeron S., Binik Y.M., Khalife S., et al.: Vulvar vestibulitis syndrome: reliability of diagnosis and evaluation of current diagnostic criteria. *Obstet. Gynecol.* 98: 45-51, 2001.
13. McKay E., Kaufman R.H., Doctor U., et al.: Treating vulvar vestibulitis with electromyographic biofeedback of pelvic floor musculature. *J. Reprod. Med.* 46: 337-342, 2001.
14. Vincenti E., Graziottin A.: I blocchi selettivi antalgici nella sindrome da vestibulite vulvare. *ALR* 12: 245-252, 2003.
15. Whiteside J.L., Walters M.D., Mekhail N.: Spinal cord stimulation for intractable vulvar pain. A case report. *J. Reprod. Med.* 48: 821-823, 2003.